

---

**ORIGINAL ARTICLE****Effect of Ethanolic Extract of *Emblica officinalis* on Histopathology of Kidney and on Biochemical Parameters in Hyperlipidemic Albino Rats**

Bheemshetty S. Patil<sup>1</sup>, Shankreppa D. Desai<sup>2</sup>, Pallavi S. Kanthe<sup>3</sup>, Potekar R. M.<sup>4</sup>, Shivkumar H.<sup>5</sup>

<sup>1</sup>Department of Anatomy, Shri B M Patil Medical College Hospital and Research Centre, BLDE University, Bijapur-586001(Karnataka)India, <sup>2</sup>Sridevi Institute of Medical Science and Research Centre Tumkur-(Karnataka)India, <sup>3</sup>Department of Physiology, <sup>4</sup>Department of Pathology, <sup>5</sup>Department of Pharmacology, BLDEA's College of Pharmacy, Bijapur-586001 (Karnataka)India

---

**Abstract:**

**Background:** It has been reported that hyperlipidemia plays a central role in the development of atherosclerosis and oxidative stress. *Emblica officinalis* also known as Amla or Indian Gooseberry acts as antihyperlipidemic and antioxidant. Its active ingredients contains tannins, gallic acid and flavonoids. **Aim & Objectives:** It was aimed to evaluate the effect of ethanolic extract of *Emblica officinalis* on histopathology of kidney and on biochemical parameters in hyperlipidemic albino Wistar rats. **Material and Methods:** Extraction of dried fruits of *Emblica officinalis* was done by Soxhlet apparatus using 99% ethanol at 60°C for 24 hours and also phytochemical analysis was done. Group I served as normal control. Group II was fed with isocaloric diet. Group III was fed with hyperlipidemic diet. Group IV was fed with isocaloric diet for 21 days + *Emblica officinalis* for 21 days. Group V was fed with hyperlipidemic diet for 21 days+ *Emblica officinalis* for 21 days. The dose of ethanolic extract of *Emblica officinalis* was taken as 100mg/kg body weight daily. **Results:** Percent body weight gain, kidney weight and nephro-somatic index significantly improved in hyperlipidemic rats treated with *Emblica officinalis*. There was a significant improvement in serum electrolyte and kidney markers. It was found that there were focal glomerular lesions with thickening of glomerulus in the kidneys of rats on hyperlipidemic diet and normal renal histology of rats on hyperlipidemic diet treated with *Emblica officinalis*. **Conclusion:** It can be concluded that *Emblica*

*officinalis* may be a good, natural therapeutic agent against hyperlipidemic diet induced oxidative damage and nephrotoxicity.

**Keywords:** *Emblica officinalis*, Hyperlipidemic diet, Histopathology of Kidney, Kidney markers, Nephrotoxicity, Serum electrolyte

**Introduction:**

Medicinal plants are nature's gift for human beings to boost a disease free healthy life. Various medicinal plants are present in a class of herbal preparations of the Indian medicine system [1]. Among many of these herbal drugs *Emblica officinalis* is one of the precious herbal drug, commonly known as Indian gooseberry or Amla which belongs to the family of Euphorbiaceae. Amla is very rich in nutrition and can be an important dietary source of Vitamin C, minerals and amino acids etc [2]. The plant also contains phenolic compounds such as tannins, saponins, phyllembelin and embilicanin. The fruit of Amla shows antioxidant, antidiabetic, hypolipidemic, antibacterial and hepatoprotective properties [3]. Along with these functions *Emblica officinalis* also may produce beneficial effects on kidney functions. Kidney contributes major role in electrolyte balance and Blood Pressure (BP) regulation. BP is regulated by renal handling of substances like Na<sup>+</sup>, Cl<sup>-</sup> and HCO<sub>3</sub><sup>-</sup>. It happens

under the control of renin angiotensin mechanism. In this way it maintains homeostasis of the body [4]. In the present study we tried to find out the effect of *Embilica officinalis* on histopathology of kidney in hyperlipidemic rats. We have given a hyperlipidemic diet to induce hyperlipidemia in albino Wistar rats to develop an animal model expressing changes in kidneys and kidney markers (serum creatinine and blood urea). High fat diets lead to atherosclerosis. It is a condition that involves the interplay of several factors like oxidation of lipoproteins and atherosclerotic plaques formation [5]. This pathogenesis could induce renal vasoconstriction followed by hypoxic condition in the kidney which promotes further ischemic renal injury. The hypoxic tissue produces reactive oxygen species (ROS) more than antioxidant present in the renal tissue. Amla as an antioxidant contains gallic acid which is a multiple hydroxyl group compound. It donates its proton to break the chain reaction of free radicals acting as an inhibitor to lipid peroxidation [6]. It was aimed to explore the nephroprotective effect of ethanolic extract of *Embilica officinalis* on renal dysfunction and pathological destructions in a hyperlipidemic rat model.

## Material and Methods

### Materials:

Healthy and good quality fresh, mature, *Embilica officinalis* (Amla) fruits were procured from the market, in the months of November–December 2012, and were identified and authenticated by the Department of Botany K.C.P. Science College, Bijapur. Extraction process was conducted in the Department of Pharmacology, BLDEA college of Pharmacy, Bijapur.

### Extraction:

300gms of the powder of dried fruits of *Embilica officinalis* (Amla) was extracted with 99% ethanol using Soxhlet apparatus at a temperature 60° C for 24 hours. The solvent was evaporated under

vacuum which gave semisolid mass with respect to the dried powder.

### Study design:

#### Experimental Animals:

Albino Wistar rats weighing 180 to 250gms were obtained from animal house of Shri B M Patil Medical college Hospital and Research Centre, Bijapur. All animals were acclimatized for 7 days to the laboratory conditions at 22-24°C maintaining a 12- hour light/dark cycle. All the experimental procedures were performed in accordance with the approval of the Institutional Animal Ethics Committee (IAEC) of Shri B M Patil Medical college Hospital and Research Centre, Bijapur. All care of animals was taken as per the guidelines of ICMR on animal research (2006) during the experiment as well as at the time of sacrifice. This study was undertaken in the Department of Anatomy. The newborn and old and diseased rats were excluded.

#### Preparation of Isocaloric Diet:

For 1kg of diet, 180gm of casein, 620gm of carbohydrate, 200gm of fat and 1% of multi vitamin and 2% NaCl were taken [7].

#### Preparation of Hyperlipidemic Diet:

For 1kg of diet, 180gm of casein, 520gm of carbohydrate, 300gm of fat and 1% of multi vitamin and 2% NaCl were taken [8].

#### Experimental Protocol

All the rats were divided into following five groups with 6 rats in each group.

Group I served as normal control fed with water and food *ad libitum*, Group II was fed with isocaloric diet for 42 days, Group-III was fed with high fat diet for 42 days, Group IV was fed with isocaloric diet for 21 days and ethanolic extract of *Embilica officinalis* (EEO) for 21 days each and Group V was fed with hyperlipidemic diet for 21 days and EEO for 21 days each. 100mg/kg body weight of EEO was given daily. [9]

**Sample collection**

Every alternate week (six rats) one group of animals were sacrificed by cervical dislocation at the end of the last dose with an overnight fast. Blood was collected in normal tubes for the separation of serum, by doing retro-orbital puncture, before sacrificing the animals.

**Tissue collection for histopathology:**

After proper dissection of animal kidneys were isolated immediately and fixed in 10% neutral buffered formalin solution for 24 hours [10]. The fixed tissues were processed routinely and then embedded in paraffin, sectioned to 3–5 μm thickness, de-paraffinized, and rehydrated using standard techniques. The extent of hyperlipidemic (high fat diet) induced necrosis was evaluated by assessing morphological changes in kidney sections stained with Hematoxylin and eosin (HandE), using standard techniques.

**Gravimetry:**

Estimation of Body Weight and Renal-somatic Index of Albino Wister rats:

**Procedure 1:**

The total body weight of each rat was recorded on the first day (beginning of experiment), Group I was fed with water and food *ad libitum*, Group III and V were fed with hyperlipidemic diet and Group II and IV were fed with iso-caloric diet for 21days and the weight was measured. The same

diet was continued from 21<sup>st</sup> to 42<sup>nd</sup> day. In addition Group IV and V were treated with EEO.

**Procedure 2:**

After 42<sup>nd</sup> day again weight was measured and after overnight fast rats were sacrificed. With proper dissection right side kidney was collected and weight was measured to the nearest of 0.1 mg on a digital weighing machine. Further the renal-somatic index was calculated by the formula of kidney weight/ total body weight.

**Estimation of Biochemical Parameters (Renal Markers and Serum Electrolytes):**

Blood Urea, Serum Creatinine, Serum Na<sup>+</sup> (Sodium), K<sup>+</sup>(Potassium), Ca<sup>++</sup> (Calcium) and Cl<sup>-</sup> were analyzed by Meril Diagnostic Kit Method.

**Statistical Analysis:**

Values were expressed as Mean ± SD. To determine the significance of inter group differences, one way ANOVA followed by 'Post Hoc t tests' were used. P ≤ 0.05 was considered statistically significant.

**Results:**

**Gravimetry**

**At 21<sup>st</sup> day:** It was observed that there was a significant increase in percent body weight gain in Group III as compared to Group I (p< 0.05). Group IV showed a significant decrease in % body weight gain as compared to Group III (p< 0.05).

**Table 1: Effect of Ethanolic Extract of *Emblica officinalis* on Percent Body Weight Gain**

Groups	Group I	Group II	Group III	Group IV	Group V	ANOVA	
						F Value	P value
On 21 <sup>st</sup> day	14.2 ± 4.7	18.5 ± 4.1	21±1.0 <sup>a</sup>	15±3.8 <sup>c</sup>	19.8±1.7	5.2	0.0061
On 42 <sup>nd</sup> day	14.5 ± 2	16.8 ± 1.4	8.9±3 <sup>a,b</sup>	8.9±3 <sup>a,b</sup>	14.6±2.1 <sup>c,d</sup>	12.2	0

Values are expressed as mean ±SD. ANOVA followed by Post Hoc Tukey's multiple comparison test.

Superscript a, b, c, d express significant difference between groups, a depicts comparison with Group I, b depicts comparison with Group II, c depicts comparison with Group III and d depicts comparison with Group V (\*P value is ≤ 0.05). Group I -normal control rats, Group II - Isocaloric diet fed rats, Group III- hyperlipidemic diet fed rats, Group IV- EEO fed rats, Group V-hyperlipidemic + EEO fed rats

**At 42<sup>nd</sup> day:** It was observed that there was a significant decrease in percent body weight gain in Group III and IV as compared to Group I and II ( $p < 0.05$ ). Group V showed a significant increase in percent body weight gain as compared to Group III and IV ( $p < 0.05$ ).

It was observed that there was significant decrease in body weight of Group II compared to Group I ( $p < 0.05$ ). There was significant increase in body weight of Group III compared to Group II

( $p < 0.05$ ). Kidney weights of Group II and Group III were lower compared to group I. Group IV which showed significant increase in kidney weight compared to Group II and Group III. Group V showed a significant relation with Groups I, II, III and IV ( $p < 0.05$ ). There was a significant decrease in renal somatic index of Group II and Group III compared to Group I. Group V showed significant relation of renal somatic index to Group II and III ( $p < 0.05$ ).

**Table 2: Effect of Ethanolic Extract of *Emblca officinalis* on Renal Somatic Index**

Parameters	Group I	Group II	Group III	Group IV	Group V	ANOVA	
						F Value	P value
Body weight (gm)	253 ± 11.4	228 ± 19.3 <sup>a</sup>	254 ± 9.6 <sup>b</sup>	236 ± 6.2	234 ± 10.2	6.24	0.002
Kidney weight (gm)	2.6 ± 0.1	0.8 ± 0.1 <sup>a</sup>	0.6 ± 0.09 <sup>a</sup>	2.5 ± 0.1 <sup>b,c</sup>	2.1 ± 0.2 <sup>a,b,c,d</sup>	223.1	0
Renal somatic Index	0.01 ± 0.0	0.003 ± 0.0 <sup>a</sup>	0.002 ± 0.00 <sup>a</sup>	0.01 ± 0.0 <sup>b,c</sup>	0.009 ± 0.0 <sup>b,c</sup>	229.3	0

Values are expressed as mean ±SD. ANOVA followed by Post Hoc Tukey's multiple comparison test.

Superscript a, b, c, d express significant difference between groups, a depicts comparison with Group I, b depicts comparison with Group II, c depicts comparison with Group III and d depicts comparison with Group V (\* P value is ≤ 0.05). Group I -normal control rats, Group II - Isocaloric diet fed rats, Group III- hyperlipidemic diet fed rats, Group IV- EEO fed rats, Group V-hyperlipidemic + EEO fed rats

**Table 3: Effect of Ethanolic Extract of *Emblca officinalis* on Kidney Markers and Serum Electrolytes**

Parameters	Group I	Group II	Group III	Group IV	Group V	ANOVA	
						F Value	P value
Blood Urea (mg%)	31±4.1	28±6.0	30±6.2	31±5.2	27±7.0	0.7	0.6717
S. Creatinine (mg%)	0.9±0.1	0.8±0.2	0.7±0.3	0.9±0.1	0.8±0.2	0.7	0.376
Na <sup>+</sup> (mEq/L)	139±2.0	143±5.0	140±1.5	139±1.8	141±4.9	2.89	0.2514
K <sup>+</sup> (mEq/L)	4.9±0.7	6.4±0.6 <sup>a</sup>	4.6±1 <sup>b</sup>	4.8±0.7 <sup>b</sup>	4.7±0.6 <sup>b</sup>	4.03	0
Ca <sup>++</sup> (mg/dl)	8.6±0.08	9.9±0.5 <sup>a</sup>	8.7±0.1 <sup>b</sup>	8.6±0.1 <sup>b</sup>	8.7±0.2 <sup>b</sup>	13.2	0
Cl <sup>-</sup> (mEq/L)	98±0.9	97±0.9	97±1.3	97±1.2	98±1.2	0.5	0.2459

Values are expressed as mean ±SD. ANOVA followed by Post Hoc Tukey's multiple comparison test.

Superscript a, b, c, d express significant difference between groups, a depicts comparison with Group I, b depicts comparison with Group II, c depicts comparison with Group III and d depicts comparison with Group V (\* P value is ≤ 0.05). Group I -normal control rats, Group II - Isocaloric diet fed rats, Group III- hyperlipidemic diet fed rats, Group IV- EEO fed rats, Group V-hyperlipidemic + EEO fed rats

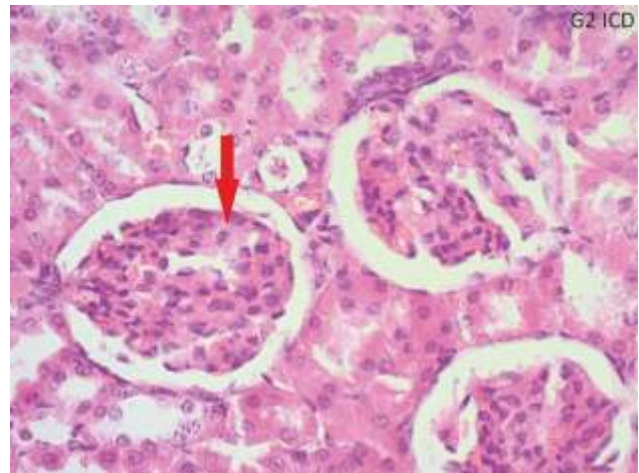


**Biochemical Parameters:**

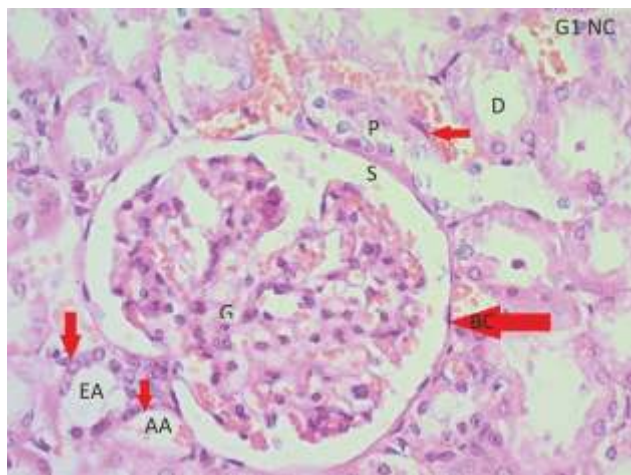
No significant differences for Blood Urea, Serum Creatinine and Serum Cl<sup>-</sup> among all Groups was observed. It is observed that the values for Na<sup>+</sup>, K<sup>+</sup>, Ca<sup>++</sup> were all significantly higher for Group II. All the other groups had similar values.

**Histopathology of Kidney:**

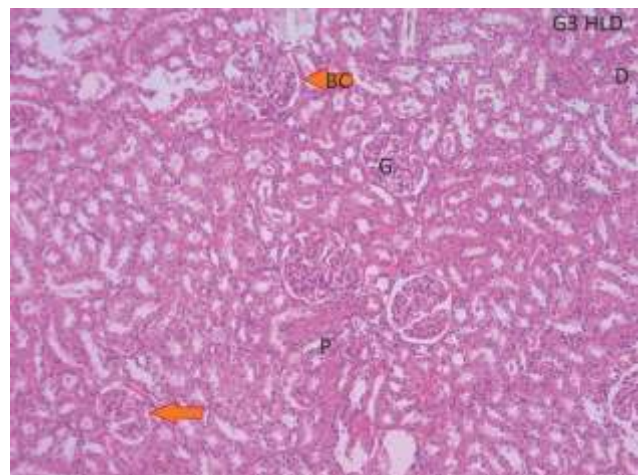
Photomicrography of H and E stained kidney of Group III hyperlipidemic (high fat diet) rats showed focal glomerular lesions including thickening of the glomerulus and normal renal tubules, whereas Group I normal control, Group II isocaloric diet, Group IV isocaloric diet with EEO and Group V hyperlipidemic diet with EEO showed normal microscopic architecture of kidney.



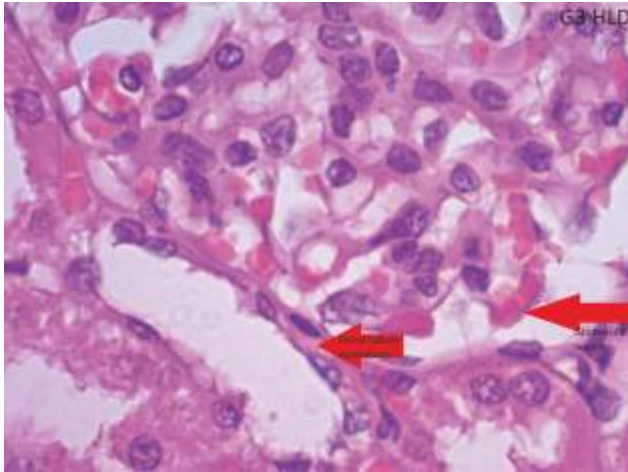
**Fig. 2: Iso-caloric Group II Rat Kidney showing Normal Architecture of Kidney and No Histopathologic changes (H and E 40X)**



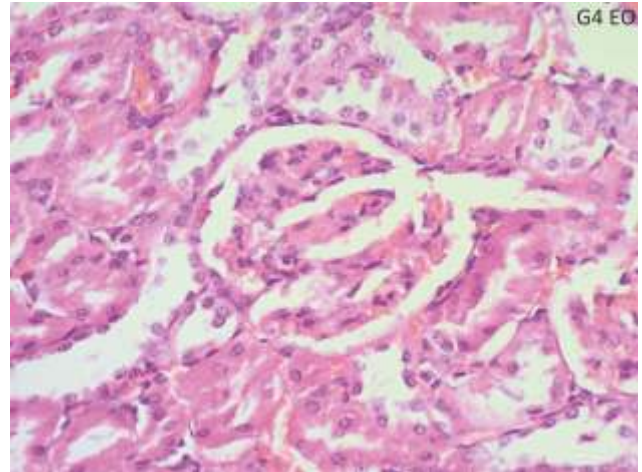
**Fig. 1: Control Group showing Normal Parenchyma and No Histopathologic Changes (H and E satin 40X) G-Glomerular, S-Space of Urine, BC- Bowmen's Capsule, P-Proximal tubule, D-Distal tubule, EA- Efferent arteriole, AA- Afferent Arteriole**



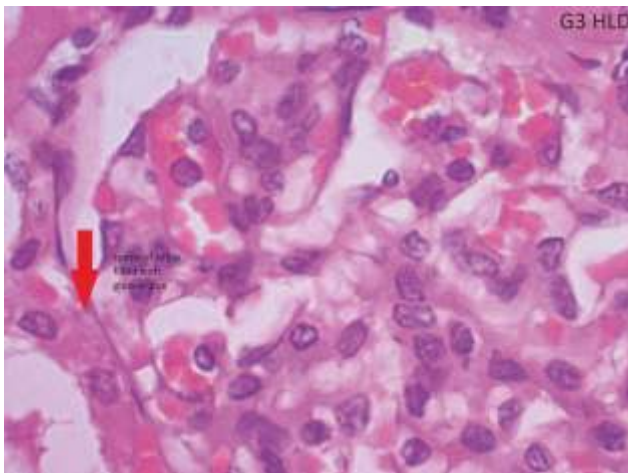
**Fig. 3: H and E stained 10 X kidney of Group III Hyperlipidemic (High fat diet) Rats showing Focal Glomerular Lesions including Thickening of the Glomerular Microscopy. G- Glomerular, BC- Bowmen's Capsule, P- Proximal Tubule, D-Distal Tubule**



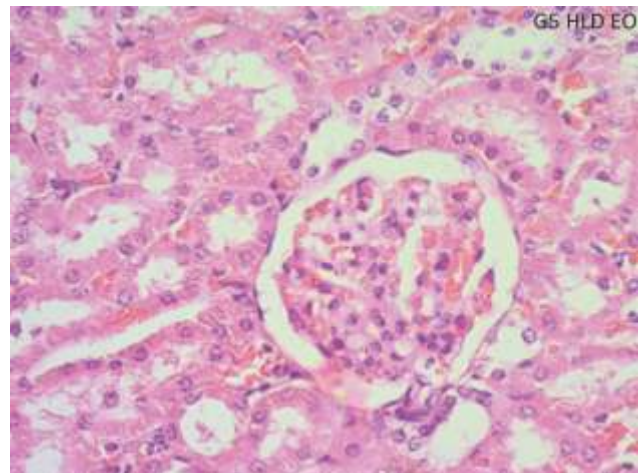
**Fig. 4:** Histopathology of H and E Stained 100 X Kidneys of Group III Hyperlipidemic (High Fat Diet) Rats showing Focal Glomerular Lesions Including Thickening of the Glomerulus and Normal Renal (DCT) Tubules



**Fig.6:** Rat Kidney of Group IV Showing Normal Architecture of Kidney and No Histopathological Changes (HandE 40X)



**Fig. 5:** Histopathology of H and E Stained 100X Kidney of Group III Hyperlipidemic (High Fat Diet) Rats showing Glomerular Thickening



**Fig.7:** H and E stained (40 X) Kidney of Group V Hyperlipidemic (High fat diet) Rats Treated with EEO showed Histopathological Changes



**Discussion:**

The study was aimed to demonstrate the nephroprotective effect of EEO to prevent the development of renal dysfunction and alteration of histopathology of kidney which are assessed by biochemical and renal markers in a hyperlipidemic rat model. Studies on such models significantly add to the knowledge towards enriching in the field of medical research. Hyperlipidemic animal models expressed changes in renal markers, biochemical parameters and histopathology of kidney. As *Emblica officinalis* being a potent antioxidant it exerts free radical scavenging activity and shows preventive role against fat induced renal toxicity [11].

It was observed no histopathologic change and no alteration of renal markers were found in rat kidneys of Group V and they also retained normal body weight. It indicates that EEO has exerted nephroprotective effect in rat kidney even when it was given hyperlipidemic diet. EEO has revealed to attenuate hyperlipidemia in Group V. EEO may be helpful to restore renal functioning due to its presence of gallic acid and tannins [6]. An increase in percent body weight gain in rats treated with EEO (Group IV) was observed compared to control rats (Group I) at 21<sup>st</sup> day ( $p < 0.05$ ). Also there was a significant increase in percent body weight gain in rats treated with EEO (Group IV) compared to hyperlipidemic rats treated with EEO (Group V) at 42<sup>nd</sup> day ( $p < 0.05$ ). There was a significant decrease in percent body weight gain in rats treated with *Emblica officinalis* (Group IV) compared to control rats at 42<sup>nd</sup> day ( $p < 0.05$ ).

Adis *et al* found that serum creatinine and bilirubin levels increased significantly in contrast media group compared to control group. Pretreatment with EEO demonstrated its nephroprotective effect by attenuating the severity of renal pathological damage and improving renal functioning [6]. In contrast we found non

significant decrease in serum creatinine and blood urea in Group V compared to Group I. Eteng *et al* showed a slight non significant increase in serum (Na<sup>+</sup>) level for Group I (100mg/kg body weight) Wistar rats [12].

We observed that Na<sup>+</sup> and K<sup>+</sup> levels were significantly lower in Group III, IV and V compared to Group II ( $p < 0.05$ ). Also there was significant increase in levels of K<sup>+</sup> in group II compared to Group I ( $p < 0.05$ ). Ca<sup>++</sup> level was significantly higher in Group II compared to Group I ( $p < 0.05$ ). Increased serum levels of triglycerides and cholesterol causes to lipid accumulation in different organs and tissues like arterial wall, liver, kidney and muscles [13]. In our study we observed the effect of (high fat diet) hyperlipidemia on the kidneys of albino Wistar rats. The hyperlipidemia caused minimum percent of lipid accumulation in kidney tissue. Histopathology of renal corpuscles exhibited normal appearance in Groups I and II (Fig.1, Fig.2) whereas Group III showed the prominent increase in the glomerular capillaries (Fig. 3, 4 and 5). Microscopic study of high fat diet i.e. Group III rat kidney showed focal glomerular lesions including thickening of glomerular changes and completely decreased space (space for urine) between glomerulus and Bowman's capsule. Epithelial cell lining of renal tubules were hemorrhagic and appeared dilated compared to normal histology of kidney. Fig. 6 and 7 both show normal histopathology, Fig. 4 and 5 show changes due to hyperlipidemia and Fig. 7 shows normal histopathology after high fat diet and treatment with EEO.

Experimental studies have shown that hyperlipidemic diet may be associated with increased oxidative stress in animals [14].

In our study we tried to assess the influences of *Emblica officinalis* on renal functions and histopathology in hyperlipidemic albino Wistar rats. From the results, *Emblica officinalis* is useful in regulating hyperlipidemia and

histopathology of kidneys in albino Wistar rats fed with hyperlipidemic diet.

### Conclusion:

In conclusion, we describe hereby distinctive renal glomerular ultrastructural injury associated with hyperlipidemia and markedly reduced alteration in renal glomerular histopathology when treated with fruit extract of *Emblica officinalis*. We would like to state that fruit extract of *Emblica officinalis* plays a protective role against hyperlipidemic diet induced oxidative damage and nephrotoxicity. The mechanistic pathways by which *Emblica officinalis* acts as a protective therapeutic against that particular toxin

is not fully clear except its antioxidant property. Further investigations are necessary to find the active functional group(s) of the compound(s) of *Emblica officinalis*. However extensive clinical studies are required to establish the efficacy and safety of *Emblica officinalis* for treating multiple pathologies associated with hyperlipidemia.

### Acknowledgement:

I sincerely thank to Dr Kusal K Das, Prof. Dept of Physiology, Shri B M Patil Medical College, Bijapur for his valuable suggestions during conducting present study as well as in writing manuscript.

### References

1. Krishnaveni M, Mirunalini S. Therapeutic potential of Phyllanthus Emblica (Amla): the Ayurvedic wonder. *Indian J Clin Biochem* 2010; 25(4):419-24.
2. Anju Lama and Hiteswar Saikia. Effects of *Emblica officinalis* (AMLA) on Serum Lipids and Atherogenesis in Albino Rats Fed with High Fat Diet. *Indian Medical Gazette* 2013; 271- 275.
3. Patel Snehal S, Goyal Ramesh K, Shah Rajendra S. Experimental study on effect of hydroalcoholic extract of *Emblica officinalis* fruits on glucose homeostasis and metabolic parameters. *Ayu* 2013, 34(4): 440- 444.
4. Filler J S. Adaptation to Renal Injury. Robert M. Brenner, Barry M. Brenner, Harrison's Principles of Internal Medicine. 17<sup>th</sup>ed. New York, NY : McGraw-Hill; 2008: 1639- 1642.
5. Bhathena Jasmine, Kulamarva Arun, Martoni Christopher. Diet-induced metabolic hamster model of nonalcoholic fatty liver disease. *Diabetes Metab Syndr Obes* 2011; 4: 195- 203.
6. Adis Tasanarong, Supranee Kongkham, Arunporn Itharat. Antioxidant effect of *Phyllanthus Emblica* extract prevents contrast-induced acute kidney injury. *BMC Complement Altern Med*. 2014; 14:138.
7. American Institute of Nutrition. Report of the AIN adhoc committee on standards of nutritional studies. *J Nut* 1977; 107: 1340-1348.
8. Mani DN, Bawankule D U, Saroj BK. Hyperlipidemic model: Studying lipid profile in small experimental animal. *Int J Pharm Pharm Sci* 2012; 4(2): 337-340.
9. Devjani Chakraborty and Ramtej Verma. Ameliorative effect of *Emblica officinalis* aqueous extract on Ochratoxin-induced lipid peroxidation in the kidney and liver of mice. *Int J Occup Med Environ Health* 2010; 23(1):63-73.
10. Manal K. Abdel - Rahman, Elham M. Mahmoud. Re-evaluation of individual and combined garlic and flaxseed diets on hyperlipidemic rats. *Pak J Nutr* 2009, 8(1): 1-8.
11. Manish K. Singh, Shailendra Dwivedi et al. Arsenic induced hepatic toxicity and its attenuation by fruit extract of *Emblica Officinalis* (Amla) in mice. *Ind J Clin Biochem* 2014; 29(1):29-37.
12. M. U Eteng, H. A. Ibekwe et al. Effect of vitamin C on serum lipids and electrolyte profile of albino wistar rats. *Nigerian Journal of Physiological Sciences* 2006, 21 (1-2): 15-19.
13. Manar E Selim, Olfat M Yousef et al. Hyperlipidemia aggravates renal disease in bacteremic male albino rats. *Journal of Medical Science*. March 2013, 1;(1): 9-22
14. Xu L, Liu Y, Wang T et al. Development and validation of a sensitive and rapid non aqueous LC- ESI MS/MS method for measurement of diosgenin in the plasma of normal and hyperlipidemic rats: A comparative study. *J Chrom B* 2009; 877: 1530-6.

\*Author for Correspondence: Dr. Bheemshetty S. Patil, Department of Anatomy, Shri B M Patil Medical College, BLDE's University Bijapur-5860071083 Email: dr.patilbs@gmail.com Cell: 09480117039